

**APHAKIC IRIS-CLAW
(ARTISAN® /VERISYSE™) LENS IMPLANTATION
IN LOW-INCOME AFRICAN POPULATION**

by

CARL-HEINZ KRUSE

A research report submitted in partial fulfilment of
the requirements for the degree of

Master of Medicine

in the

Department of Ophthalmology
Nelson R. Mandela School of Medicine
University of KwaZulu-Natal
Durban

2007

ABSTRACT

Purpose: To test the viability of implanting the Artisan®/Verisyse™ lens in a low-income monocular aphakic African population with insufficient capsular support where contact lens wear is expensive and spectacle correction is not possible, by assessing the post-operative visual functions. To further assess whether adverse effects (e.g.: pigment dispersion with secondary glaucoma, prolonged uveitis) in patients with highly pigmented irises would be as low as with patients in European and American trials.

Methods: A prospective, randomised, controlled clinical trial comparing outcomes in two groups of unilateral aphakic patients. The patients in the first group received an Artisan intra-ocular iris-claw lens as a secondary procedure while the second group remained aphakic (the current treatment status quo for public patients in KwaZulu-Natal province in South Africa). Follow-up was done for 1 year.

Results: The study was terminated early due to ethical and statistical reasons. Nine treated and five control patients were included. Monocular uncorrected vision was significantly higher in the treatment group ($P=0,012$) and patient satisfaction was higher ($p=0,002$). Changes in other variables (intraocular pressure, angle pigmentation, change in cup-to-disc ratio, iris pigment changes and best spectacle corrected vision) were not significantly different between the two groups.

Conclusion: The Artisan®/Verisyse™ lens is a feasible option for aphakic African patients with regard to visual outcome, safety and patient satisfaction. This form of refractive correction should be the standard for patients with no capsular support and where other options are too expensive or carry greater risk.

DECLARATION

I hereby declare that this research report is my own unaided work. It is being submitted for the degree of Master of Medicine (Ophthalmology) in the Nelson R. Mandela School of Medicine, University of KwaZulu-Natal, Durban. It has not been submitted before for any degree or examination at any other university.

_____ day of _____ 2007.

PREFACE

This study represents original work by the author and has not been submitted in any form to another university. Where use was made of the work of others, it has been duly acknowledged in the text. The research described in this dissertation was carried out in the Department of Ophthalmology, Nelson R. Mandela School of Medicine, University of KwaZulu-Natal under the supervision of Dr. Linda Visser MBChB FCOphth (SA) MMed (Ophth), Head of Department of Ophthalmology.

CONTENTS

		Page
Chapter 1	Introduction	1
Chapter 2	Review of Literature	4
Chapter 3	Patients and Methods	11
Chapter 4	Results	22
Chapter 5	Discussion	34
Chapter 6	Conclusion	38
	References	39
	Annexures	42

LIST OF PLATES

Plate 1	Aphakic spectacles	5
Plate 2	Unrestricted pupil dilatation with Artisan lens	9
Plate 3	Randot stereograms with polarised glasses	16
Plate 4	Pigment loss at enclavation site	31
Plate 5	Heavily pigmented angle	32
Plate 6	Damage due to initial insult	35
Plate 7	Pseudoexfoliation and aphakia	36

LIST OF FIGURES

		Page
Figure 1	The Artisan® or Verisyse™ lens	8
Figure 2	Surgical Procedure	19

LIST OF TABLES

Table 1	Study outcomes	23
Table 2	Report on outcomes	24
Table 3	Test statistics on outcomes	24

LIST OF GRAPHS

Graph 1	Change in monocular uncorrected visual acuity	25
Graph 2	Change in bilateral uncorrected visual acuity	26
Graph 3	Monocular best spectacle corrected visual acuity	27
Graph 4	Binocular best spectacle corrected visual acuity	27
Graph 5	Change in intraocular pressure (IOP)	30
Graph 6	Change in cup-to-disc ratio	30
Graph 7	Change in angle pigmentation	32
Graph 8	Patient satisfaction score	33

ACKNOWLEDGEMENTS

I wish to express my sincere gratitude to the following people for their assistance in preparation of this dissertation:

1. Dr Linda Visser, Head of Department of Ophthalmology for her expert guidance in this long process.
2. Professor Anne Peters, previous Head of Department of Ophthalmology under whose guidance this study was begun.
3. The consultants, registrars and medical officers in the Department of Ophthalmology without whose assistance this dissertation would never have come to fruition.
4. The medical and optometric personnel at St. Aidan's Regional, Addington and Inkosi Albert Luthuli Hospitals.
5. Ms. Tonya Esterhuizen, Department of Biostatistics for the statistical planning and analysis.
6. Visicare and Ophtec BV for sponsoring the Artisan® lenses used in this study.

Chapter 1

INTRODUCTION

Cataract formation, the opacification of the lens of the eye, is the leading cause of blindness in the world. It is estimated that 43% of all blindness is due to cataract and that 90% of the blind live in Asia or Africa¹.

Although cataract is a treatable condition, there is still a global net increase of blindness of 1 to 2 million people per year mostly due to population growth, increasing numbers of elderly and paucity of eye care in underdeveloped areas. Cataract surgery is therefore a phase 1 priority for the global Vision 2020 program in an effort to eliminate avoidable blindness by the year 2020.

Cataract surgery has evolved over the years to be a highly successful and safe operation. Cataract surgery started as a procedure that removed the lens in total along with its capsular bag. This resulted in an eye without a lens that required thick spectacles (aphakic or “pebble” glasses) with their consequent optical disadvantages, in an effort to correct the resulting refractive error. Current operations differ in that surgeons remove only the anterior capsule and the nucleus of the lens and replace it with a synthetic lens that is sited in or on the remaining capsular bag. This obviates the need for aphakic spectacles.

Today cataract surgery has a complication rate of between 2% and 10%. Most complications can be satisfactorily managed to give the patient good vision but some complications such as unintentional loss of the capsular bag may have lasting sequelae.

This established practice is compared in this study to implantation of an emerging alternative intraocular device, the Artisan®/Verisyse™ iris-fixated lens.

Chapter 2

REVIEW OF LITERATURE

2.1 Methods of Correcting Aphakia

The natural crystalline convex lens of the eye has an effective power of approximately +20 dioptres². Removal of the cataractous lens therefore leaves the eye with a large refractive error. There are several ways to correct this error.

2.1.1 Intraocular Lens

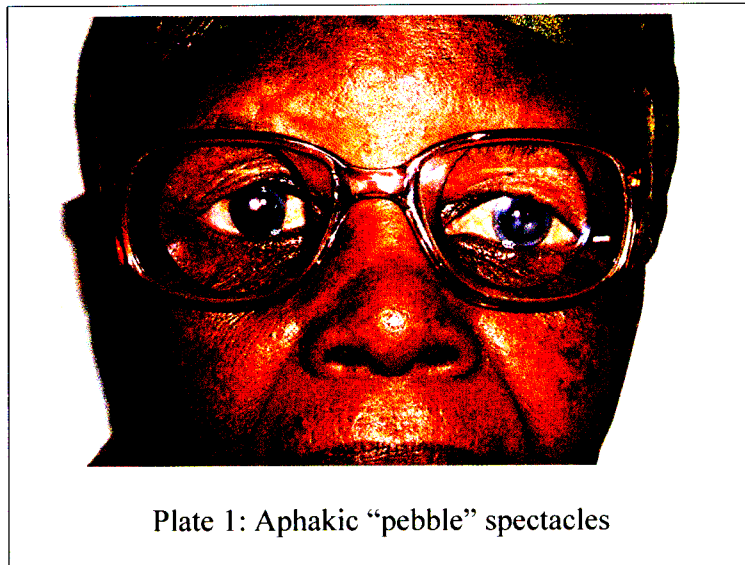
Since the advent of extracapsular cataract extraction it has been possible to place an artificial lens into or on top of the remaining lens capsular bag. This has become the global accepted method of correction due to the safety, predictability and visual results³. This method of lens placement necessitates that a lens capsule remains in position behind the iris after the cataract has been removed. Support to the lens is supplied by the bag itself as well as by its suspending zonules.

2.1.2 Spectacles

Before the introduction of intraocular lenses, refractive error correction after cataract surgery was achieved by using aphakic spectacles (Plate 1). These glasses have an average power of between +10 and +15 dioptres and therefore are very thick and heavy.

Besides the discomfort factor these spectacles produce numerous optical aberrations². These thick convex lenses magnify the image perceived by the eye. In bilateral aphakic

eyes this produces a feeling of everything being closer than it really is and patients often struggle to perform simple tasks such as descending stairs.



In unilateral aphakic eyes full spectacle correction is impossible because of the different image sizes². The brain can normally successfully fuse two images of a difference in size of up to 10%. The magnification produced by aphakic glasses is, on average, 33%.

Thick lenses also give the barrel illusion (straight lines curve in at the periphery), ring scotoma (ring of absent vision at the edge of the glasses), jack-in-the-box phenomena (objects suddenly appearing out of the scotoma into view) and reduced visual field².

2.1.3 Contact Lens

Because contact lenses lie closer to the optical centre of the eye, they cause very little magnification and almost no optical aberrations². They can therefore be successfully used in monocular aphakic eyes.

Correct care, attention and hygiene need to be maintained but the main deterrent for contact lens use in state hospitals in the greater Durban region, is the cost. Although

contact lenses are less expensive than intraocular lenses, they need to be replaced at regular intervals. For an indigent population this cost is often impossible to maintain.

2.1.4 Scleral-Fixated Lens

One method to employ intraocular lenses in the absence of a suitable capsular bag is to attach the lens to sclera. Scleral-fixated lenses are designed with two small loops that are used to suture the lens just posterior to where the bag and zonules usually attach to the choroid.

The sutures are passed through the sclera and its underlying pars plana, which is situated between the vascular ciliary body and the retina. This technique was introduced in 1986 and has gained acceptance in many centres due to the theoretical reduction in risk of iris chafe, iritis, pigment dispersion and cystoid macular oedema.

The technique is, however, technically difficult because it involves blindly placing fixation sutures through the ciliary sulcus close to the major arterial circle of the iris. Inadvertently damaging the ciliary body or the retina during this procedure can lead to ciliary tenderness (30%), vitreous haemorrhage (2–5%), cystoid macular oedema (13,2%) or retinal detachment (3,3%)⁴.

The most common problem associated with conventional transscleral fixation has been tissue erosion and resultant exposure of the suture through the conjunctiva, which can lead to open communication with the interior of the eye and predispose to endophthalmitis or accelerate suture breakage.

The teaching nature of our hospitals, the indigent population served and the inexperience in using this technique precludes us from using scleral fixation to correct aphakia.

2.1.5 Angle Supported Lens

In contrast to the standard intraocular and scleral-fixated lenses the angle supported lens is placed anterior to the iris in the anterior chamber. The haptics supporting the optic of the lens are positioned into the angle between the cornea and the iris. This gives rise to the potential of damaging the trabecular meshwork in this area.

Before the early 1980s angle supported lenses were the implants of choice because of ease of insertion and relatively short operating time. In the mid-1980s, however, it became evident that these ridged lenses were associated with many complications.

In patients with dark irises there has been even less success. An unacceptable complication rate, especially in African patients, includes pigment dispersion due to rubbing on the iris, chronic uveitis (30%) or inflammation (16%) and glaucoma (5%) due to angle damage^{5,6}.

The later versions of these lenses have been reasonably successful (in eyes with light irises) due to the softer and longer haptics, smooth surface and small surface area against the trabecular meshwork. Several recent studies have suggested improved results with these modern devices, however, they lack adequate scrutiny of angle and endothelium damage over time.

In many centres angle supported lenses are reserved for patients with light irises and an expected lifespan of less than 20 years due to the risk of long term creeping angle damage and glaucoma.

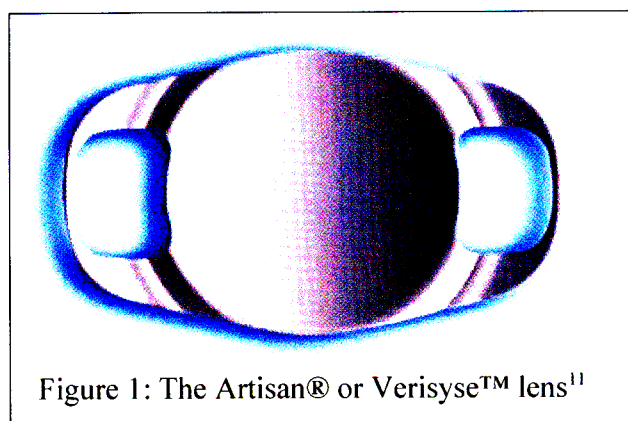
2.1.6 Aphakia

The difficulty in correcting monocular patients successfully often necessitates leaving the one eye with uncorrected refractive error. The uncorrected eye receives an unfocused image, therefore no diplopia is apparent. The patient essentially functions with only one eye. The uncorrected eye thus serves as a “backup” should the normal eye ever become blind in the future.

2.2 The Artisan®/Verisyse™ Lens

2.2.1 History

The first iteration of the Artisan lens appeared in 1978^{7,8}. The lens was designed by Prof. Dr. Jan G. F. Worst and manufactured by Ophtec BV, Groningen, the Netherlands. The lens was initially designed for correcting aphakia following cataract surgery but further modifications in 1986 allowed the lens to be used to correct refractive errors even in phakic patients^{7,8,9,10}. Other modifications included toric correction for astigmatism (1995), opaque lenses for pupil occlusion in intractable diplopia (1984), custom made lenses for iris reconstruction, paediatric lenses and foldable lenses for small incision surgery (2003)¹¹.



2.2.2 Lens Design¹¹

The Artisan aphakic lens consists of a central optic of 5mm in diameter and two “claw” haptics on opposite ends (Figure 1). The entire lens is made of immunologically inert

PMMA (polymethyl methacrylate). The total lens length is 8.5mm and weighs 8mg. Each haptic consists of a flexible complete loop that has been cut through the middle to provide a small gap.

What makes this lens unique is its fixation technique. The lens is also placed into the anterior chamber similar to the angle supported lenses but the haptics attach to the base of the iris. The fixation technique is called enclavation by which small bridges of iris are forced into the gap in the haptics.

2.2.3 Long-term clinical experience

Artisan lenses have been tested extensively in Europe and North America^{9,15}. These trials have shown that the surgical risk is no greater than that of standard cataract operation and posterior chamber lens implant.

The lens has been shown to allow virtually unrestricted pupil dilatation (Plate 2) since the lens is attached to the midperipheral immobile iris.



Plate 2: Unrestricted pupil dilatation with Artisan lens¹¹

Fluorescein angiographic studies¹² have shown no leakage of the iris vessels at the enclavation site. In addition, no continuing iris atrophy has been reported¹³. This is in stark contrast to the Binkhorst iris rim fixated lenses, used in the past, which caused uveitis, iris atrophy, glaucoma and corneal decompensation¹¹.

The two diametrically opposed haptics give stable fixation and the lens has remained stable even in 4-year follow up trials^{14,15}. The fixation technique has not changed for the last 25 years. Predictability of the desired refraction is within 1 dioptre⁹ and no patient has experienced a drop in best spectacle corrected vision⁹.

The European Multicentre Study found no serious side-effects after Artisan implantation⁹. Minor adverse events in the US Phase III Clinical Investigation¹⁵ included postoperative glare (7.7%), iris pigment precipitates (7.2%) and haloes (5.3%). Other problems, such as corneal oedema and chronic inflammation, were found to be rare (<1.5%) at four years follow up. No cases of glaucoma or increased intraocular pressure were identified.

The biggest apprehension was directed at the close proximity of the lens to the endothelial surface of the cornea. It was felt that endothelial cell loss could pose the biggest risk for Artisan lens failure. Studies, however, have shown a loss of 1.3% to 4.5% if the initial anterior chamber depth was more than 2.8mm^{9,16,17,18}. The US phase III clinical trials (550 patients at 22 sites) surprisingly showed an increase of cell density of 5.8% at 2 years.

It must be kept in mind that the vast majority of patients used in these trials were Caucasians and had relatively little iris pigment. No study to date has looked at the effects and outcomes of using the Artisan®/Verisyse™ lens in African patients only.

Chapter 3

PATIENTS AND METHODS

3.1 Study Plan

3.1.1 Purposes

- To test the viability of an alternative method of correction in a low-income, monocular, aphakic, African population where contact lens wear is expensive and spectacle correction is not possible, by assessing the post-operative visual acuity (both monocular and binocular) and stereopsis.
- To assess whether adverse effects (e.g.: pigment dispersion with secondary glaucoma and post-operative or prolonged uveitis) in patients with highly pigmented irises would be as low as in patients in European and American trials.
- To assess patient satisfaction with the procedure as compared to the current status quo of leaving monocular aphakic eyes with inadequate capsular support, aphakic.

3.1.2 Hypothesis

The Artisan®/Verisyse™ lens is a feasible option for aphakic African patients with regard to visual outcome, safety and patient satisfaction.

3.1.3 Study Design

Prospective, randomised, controlled clinical trial comparing outcomes in two groups of unilateral aphakic patients. The patients in the first group received an Artisan intraocular

iris-claw lens as a secondary procedure while the second group stayed aphakic (the current treatment status quo for monocular aphakic eyes with insufficient capsular support).

The patients had to be followed up for a year and the author gathered all information. Statistical analysis was done by the Department of Biostatistics at the University of KwaZulu-Natal.

The study was submitted and approved by the Bioethics Board as well as the Postgraduate Committee of the University of KwaZulu-Natal. Safety and ethical issues were continually evaluated by the author and his supervisor under the obligations to the Board.

3.2 Study Procedure

Trial patients were sourced from the eye clinics of the hospitals of the Department of Ophthalmology of the University of KwaZulu-Natal.

3.2.1 Inclusion criteria were as follows:

- Black African patients: The study was aimed at the effects of the Artisan lens on heavily pigmented irises.
- Unilateral aphakic patients with vision in the other eye 6/18 or better: It was considered unethical to test the lens on both eyes of a patient. Although bilateral aphakic eyes (without capsular support) might have better refractive correction with Artisan lenses this had not yet been proven. Aphakic spectacles were a safe alternative. Monocular aphakic patients could not be satisfactorily corrected with aphakic glasses².

- No support for posterior chamber lens: Patients with support for posterior chamber lenses should receive them since they had been proven to be extremely successful even in eyes with heavily pigmented irises³.
- Informed consent by the patient: All patients entered into the study had to understand and agree to be in the study. Patients then randomised to the Artisan arm of the trial had to sign a further consent regarding the surgery.

3.2.2 Exclusion criteria

- Intraocular pressure > 21mmHg (treated) in established glaucoma: High intraocular pressure is a contraindication for intraocular surgery because of the risk of suprachoroidal haemorrhage. Established but successfully treated glaucomatous eyes were excluded because one of the outcomes being studied included intraocular pressure and glaucomatous changes. Ocular hypertensives were not excluded unless the pressure stayed persistently above 21mmHg with treatment.
- Pupil width of more than 5mm under mesopic (moderate light) conditions: The lens has previously been attached successfully to irises with bigger pupillary apertures but it was felt that the risk of dislocation of the lens into the vitreous during surgery was too high for this trial.
- Significant iris pathology: Since we wanted to study the effects of the lens on the iris, eyes were excluded if the author thought the iris pathology severe enough to

interfere with the outcome. Slight, diffuse iris atrophy or small pupillary notches were not taken as exclusion factors.

- Severe diabetic eye disease: Patients with clinically significant maculopathy, proliferative or severe non-proliferative diabetic retinopathy, had a high chance of not reaching optimal vision after the surgery. Diabetics with mild or no diabetic eye disease were not excluded.
- Chronic or recurrent uveitis/iritis: One of the study outcomes was chronic inflammation after lens implantation. All other reasons for uveitis had to be excluded.
- Rubeosis iridis: The risk of bleeding was too high if a lens were to be clipped onto a rubeotic iris.
- Anterior chamber depth less than 2.8mm as measured by the Smith method¹⁹: Previous studies had shown a risk for endothelial damage if the anterior chamber was shallower. A depth of at least 2.8mm results in the implanted lens being at least 1mm away from the cornea.
- Corneal pathology: Corneal scarring, irregularities or opacities would prevent the eye from achieving optimal vision after surgery.
- Eyes with ocular pathology where no improvement in visual acuity after surgery was anticipated were excluded (e.g. retinal disease).

- Age below 18 years: All patients had to be able to understand, consent and sign for himself or herself regarding the trial.
- Patients where assessment and biometry in the clinic was not possible (e.g. severe Parkinson's disease) were excluded.
- Patients were not included in the trial if they believed there were any reasons that they would not be able to attend the required follow up visits (e.g.: emigrating or lack of transport)

3.2.3 Randomisation

Eligible patients were randomised into two groups. Randomisation occurred after consent for the trial had been obtained and the patient examined for inclusion and exclusion factors.

Randomisation occurred by the patient choosing an envelope containing the data sheets for either the treatment or the control arm. Care was taken to make the envelopes identical in all respects. The envelopes were mixed so that neither the patient nor examiner could identify the sheets prior to opening.

3.2.4 Consent


All patients were counselled about the trial before randomisation. Translators were utilised where necessary to ensure understanding. Information sheets about the trial in English (Annexure A) and IsiZulu approved by the Bioethics Department were given to each

participant to take home. Patients randomised to the treatment arm were asked to sign a further consent form (Annexure B) regarding the surgical procedure.

3.2.5 Outcomes

The following primary outcomes were looked at during the 1 year follow up:

- **Stereopsis:** It was expected that no patients would have 3-dimensional vision with monocular aphakia due to the severely defocused image of one eye. Final 1 year outcomes were measured to see what percentage of patients regained stereopsis. Stereopsis was measured as minimum degrees of arc resolvable using polarised glasses with Randot Stereograms (Plate 3).



- **Monocular visual acuity:** Since the aim of implanting the Artisan lens was to improve vision in the eye this was the major measurable outcome. Both uncorrected as well as best spectacle corrected visual acuities were measured using Snellen Charts. All measurements were done by qualified optometrists.

- Binocular visual acuity: Binocular visual acuity in two eyes with similar vision is often slightly better than monocular vision. This outcome was also studied.
- Patient satisfaction: This is the only subjective primary outcome but considered important since the aim of this study was to try and improve the quality of life of these and future patients. Satisfaction was graded on a scale of 1 to 5:
 - 1: Definitely worse
 - 2: Not worth it
 - 3: Same
 - 4: Improvement
 - 5: Very happy

The following secondary outcomes were examined:

- Iris atrophy and pigment dispersion: It was unknown how dark irises responded to direct contact of the Artisan lens clipped to it. Angle supported lenses led to pigment dispersion in these patients⁵.
- Uveitis: Postoperative inflammation duration and severity was observed.
- Intraocular pressure and glaucoma: Since angle supported lenses led to angle destruction and elevated pressure with eventual glaucoma⁵ this outcome was closely monitored in this study of iris-claw lenses.
- Other complications: All other unexpected adverse events were assessed. Potential complications included corneal and iris damage, corneal decompensation, retinal detachment, lens dislocation, irregular pupil, infections and hypopyon.

The following aspects were not studied:

- Endothelial cell counts: No endothelial cell counting equipment is available in the province of KwaZulu-Natal. All previous research^{9,16,17,18} has shown stability of the endothelial cells after Artisan lens implantation and there should be no reason why corneas in eyes with dark irises should behave any differently.

3.3 Surgical Procedure

Surgery took place within the existing ophthalmology slates. No additional personnel or support services were required.

The surgery was done by senior ophthalmic surgeons who had been adequately trained to do the procedure (Annexure C). Complete sterile technique and usual care was taken of the patients similar to patients being admitted for regular cataract surgery.

- All surgery was done under local anaesthesia by administration of a parabolbar block with 4ml Peterkaien® (2% lignocaine), 2ml Macaine® (0.5% bupivocaine) and 150IU Hyalase® (Hyaluronidase).
- A superior peritomy was made in the conjunctiva.
- A partial thickness 12 o' clock corneo-scleral or scleral tunnel incision (5-6mm) was created. Care was taken not to enter the anterior chamber.
- A 2mm paracentesis was made on either side of the main incision at the limbus (figure 2.1).

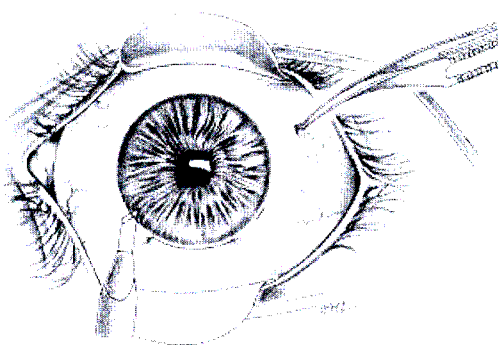


Figure 2.1: Paracentesis

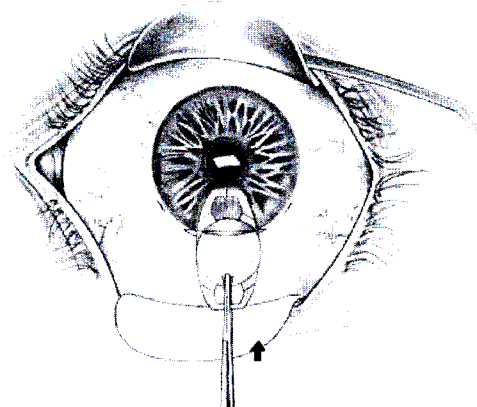


Figure 2.2: Lens insertion through main wound

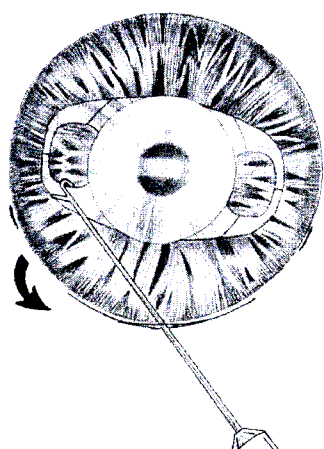


Figure 2.3: Lens rotation
iris

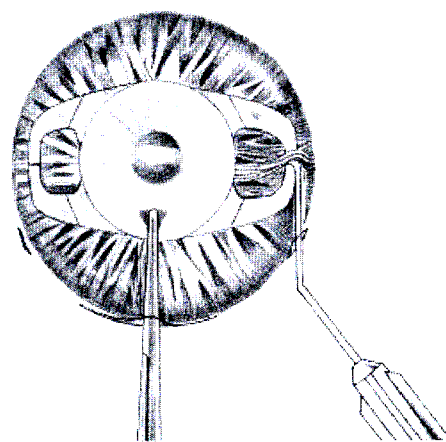


Figure 2.4: Lens stabilised while enclaving

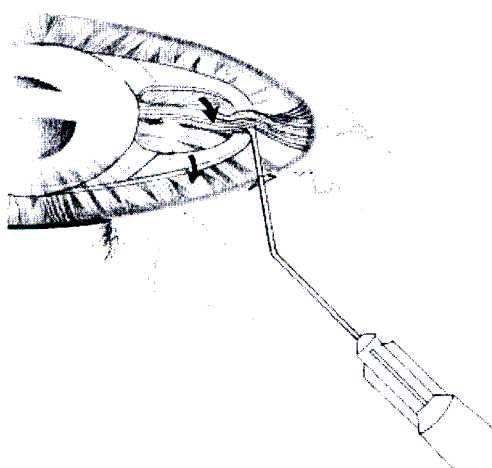


Figure 2.5: Iris enclavation

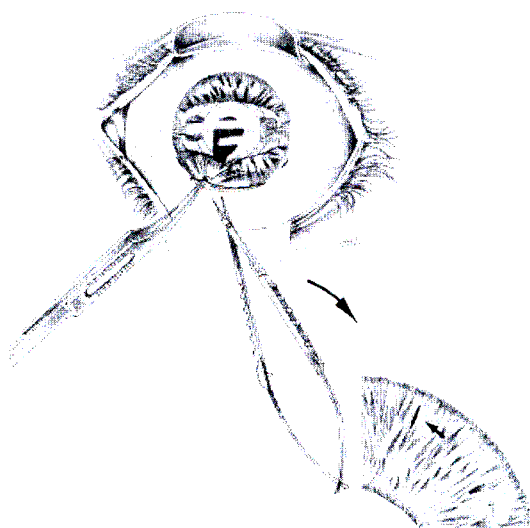


Figure 2.6: Radial iridectomy

- Myochol™ was injected into the anterior chamber if the pupil needed to be constricted.
- A viscoelastic was injected to protect the corneal endothelium.
- The main incision was deepened to enter the anterior chamber.
- The lens was inserted into the anterior chamber (figure 2.2) and rotated into the correct position (figure 2.3).
- A bubble of air was injected under the iris to lift and support it.
- The iris knuckle was enclaved into the lens claws (figures 2.4 and 2.5).
- A small radial iridectomy was performed (figure 2.6).
- The viscoelastic and air was removed.
- The wound was closed with 2-4 sutures.
- Chloramphenicol Minims® 0,5% drops and subconjunctival steroid-antibiotic mixture (0,5ml Celestone® and 0,5ml Amikin®) was administered.
- The eye was patched for 12 hours.
- The patient was given topical drops to use at home: Spersadex Comp® steroid with antibiotic, and Acular® non-steroidal anti-inflammatory.

3.4 Statistical Analysis

The project was discussed with a professional statistician at the University of KwaZulu-Natal.

Based on the outcome of stereopsis the expected effect size was an increase from 0% of patients having stereopsis in the control arm to 50% in the treated arm. At 80% power and 95% confidence 15 subjects were needed in each arm - a total of 30 participants.

With binocular visual acuity outcome the expected effect size was a mean decrease of 0.25 MAR in treated relative to control subjects. If control subjects had an expected mean MAR of 3 and SD of 0.4 in both groups, 18 subjects per group (36 in total) would have 83 % power to detect a significant difference between the groups based on the aforementioned assumptions.

Monocular visual acuity was expected to increase even more dramatically than binocular visual acuity, thus 18 participants per group was considered adequate for all main outcomes.

Continuous outcomes would be compared between the two groups using independent t-tests or Mann Whitney tests where appropriate. Categorical outcomes would be compared using Chi Square or Fisher's exact tests where appropriate.

Chapter 4

RESULTS

4.1 Study Termination

Patient enrolment began early 2005 and in November 2007 a total of 15 patients had been enrolled. This fell far short of the 36 patients needed but an interim analysis was requested due to ethical concerns by the author.

Although only 9 patients had been enrolled in the treatment (Artisan implantation) and 6 in the control, the study was terminated early due to statistical and clinical concerns.

4.2 Statistical Interim Analysis

The statistical analysis was performed by the Department of Biostatistics at the University of KwaZulu-Natal in November 2007. On the basis of these results the statistician recommended immediate study termination. Details of outcomes are found in Table 1.

Comparability of the intervention and control groups in terms of demographics was performed using Chi square or Mann-Whitney tests where appropriate. This was due to the small sample size in each group.

There was no statistical difference between the two groups in terms of gender ($p=0.580$), age ($p=0.689$) or cause of aphakia (trauma/ complicated surgery/ spontaneous lens dislocation) ($p=0.287$).

Patient Details					Aphakia		Initial Visit					Final Visit (Nov 2007)										
?	Surg	Date	Age	Sex	Hosp	Trauma	T since	UCVA1	2	BSCV1	2	IOP	Pm	C:D	3D	UCVA1	2	BSCV1	2	IOP	Pm	C:D
Y 1	2006/03/16	43	m		SAH	Trauma	2004/10/13	0.0167	1	0.67	1	15	1	0.4	40	0.67	1	1	1	13	2	0.4
Y 2	2006/05/19	71		f	SAH	Surgery	2005/06/16	0.05	0.25	0.67	0.67	10	1	0.4	80	0.5	0.5	0.67	0.67	12	1	0.4
Y 3	2006/10/20	48	m		ADH	Trauma	2006/06/15	0.05	1	0.67	1	18	2	0.4	40	1	1	1	1	16	2	0.4
Y 4	2007/02/08	75		f	ADH	Surgery	2006/12/08	0.05	0.67	0.67	0.67	13	3	0.3	200	0.5	0.67	0.67	1	12	3	0.3
Y 5	2007/05/23	57		f	IALC	Surgery	2006/02/16	0.0167	0.67	0.33	0.67	29	3	0.2	800	0.17	0.8	0.33	1	35	3	0.3
Y 6	2007/08/20	59	m		IALC	Surgery	2006/07/26	0.05	0.67	0.25	1	20	3	0.1	-	0.017	0.67	0.13	0.8	19	3	0.1
Y 7	2007/08/20	67	m		IALC	Surgery	2007/05/25	0.1	0.67	0.5	0.67	14	1	0.4	80	0.67	0.67	1	1	22	1	0.4
Y 8	2007/09/27	77		f	IALC	Spont	2007/02/27	0.05	0.33	0.8	0.8	16	3	0.4	-	0.5	0.5	1	1	18	3	0.3
Y 9	2007/10/16	46		f	SAH	Surgery	2007/05/23	0.1	0.33	0.67	0.67	13	2	0.3	-	0.5	0.5	0.5	0.5	14	2	0.3
N 1	2006/03/30	77		f	SAH	Surgery	2005/01/12	0.0083	0.67	0.17	1	16	2	0.2	-	0.02	0.67	0.17	1	15	2	0.2
N 2	2007/05/23	56		f	IALC	Surgery	2006/02/16	0.0167	0.7	0.33	0.67	29	3	0.2	-	0.0083	0.67	0.33	0.67	36	3	0.2
N 3	2006/05/12	66	m		SAH	Surgery	2005/02/15	0.05	0.17	0.8	0.67	12	0	0.4	-	0.05	0.17	0.8	0.67	12	0	0.4
N 4	2006/05/16	71		f	SAH	Surgery	2006/06/22	0.05	0.67	1	1	19	2	0.5	-	0.05	0.67	1	1	13	2	0.5
N 5	2007/08/28	65		f	SAH	Surgery	2007/08/22	0.05	0.05	0.67	0.17	31	2	0.2	-	0.05	0.1	0.67	0.67	24	2	0.3
N 6	2007/10/26	51		f	SAH	Surgery	2007/10/11	0.0167	0.1	0.5	0.67	20	3	0.3	-	0.0167	0.1	0.5	0.67	20	3	0.3

? = Did the patient get an Artisan implant?

Surg Date = Date of surgery (or first consult if no lens was implanted)

Cause = Cause of aphakia

T since = When did the eye become aphakic?

UCVA1 = Uncorrected vision 1 eye in logMAR (2 = binocular)

BSCVA1 = Best spectacle corrected vision 1 eye (2 = binocular)

IOP = Intraocular pressure (**untreated**) in mmHg

Pm = Pigment in angle (0 to 3)

C:D = Cup:disc ratio

3D = Stereopsis in minutes of arc

⊕ = Patient satisfaction (5 = best)

Table 1: Study outcomes

Comparison of the change in final outcomes between the two groups (non-parametric Mann-Whitney tests were used due to small sample sizes) was made for the major and minor outcomes (Table 2 and 3).

Group		Change in uncorrected vision 1 eye (logMAR)	Change in uncorrected vision 2 eyes (logMAR)	Change in corrected vision 1 eye (logMAR)	Change in corrected vision 2 eyes (logMAR)	Change in IOP (mmHg)	Change in angle pigment (0-3)	Change in C:D ratio	Satisf. (1-5)
Intervention	Med	.4500	.0000	.0000	.0000	1.000	.000	.0000	5.00
	Min	-.03	.00	-.17	-.20	-2.0	.0	-.10	3
	Max	.95	.25	.50	.33	8.0	1.0	.10	5
Control	Med	.0000	.0000	.0000	.0000	-.500	.000	.0000	3.00
	Min	-.01	.00	.00	.00	-7.0	.0	.00	2
	Max	.01	.05	.00	.50	7.0	.0	.10	3
Total	Med	.1500	.0000	.0000	.0000	.000	.000	.0000	4.00
	Min	-.03	.00	-.17	-.20	-7.0	.0	-.10	2
	Max	.95	.25	.50	.50	8.0	1.0	.10	5

Table 2: Report on outcomes

Test	Change in uncorrected vision 1 eye	Change in uncorrected vision 2 eyes	Change in corrected vision 1 eye	Change in corrected vision 2 eyes	Change in IOP	Change in angle pigment	Change in C:D ratio	Satisf.
Mann-Whitney U	6.000	17.500	21.000	26.500	19.000	24.000	23.000	2.500
Wilcoxon W	27.000	38.500	42.000	47.500	40.000	45.000	68.000	23.500
Z	-2.506	-1.335	-.799	-.064	-.949	-.816	-.675	-3.155
Asymp. Sig. (2-tailed)	.012	.182	.425	.949	.343	.414	.500	.002
Exact Sig. [2*(1-tailed Sig.)]	.012(a)	.272(a)	.529(a)	.955(a)	.388(a)	.776(a)	.689(a)	.002(a)

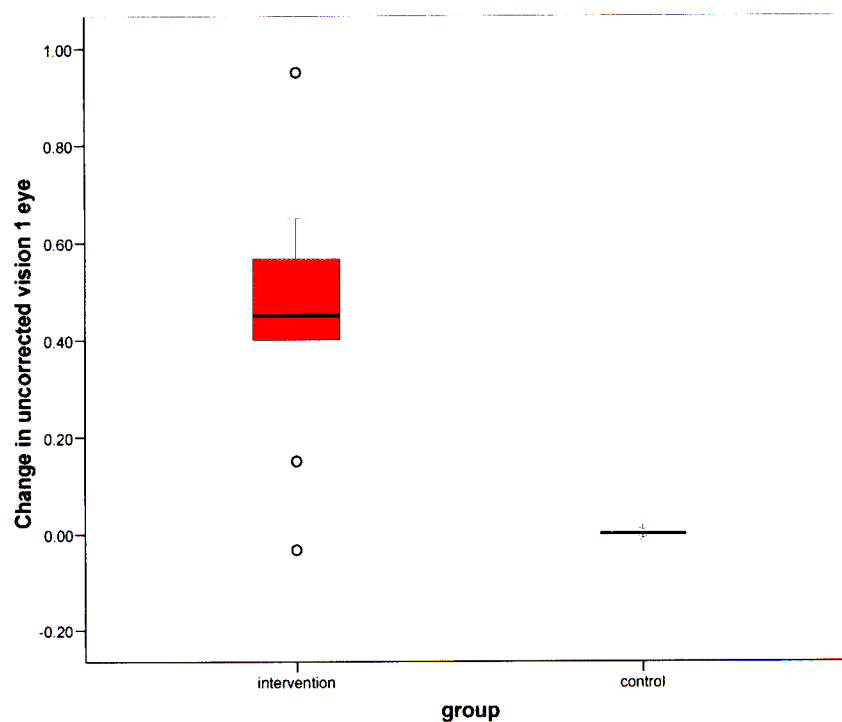
Table 3: Test statistics on outcomes

Change in the monocular uncorrected visual acuity was significantly higher in the treatment group compared with the control group ($p=0.012$). Satisfaction was significantly higher in the treatment group than in the control group ($p=0.002$). Changes in other variables (intraocular pressure, angle pigmentation, change in cup-to-disc ratio, monocular

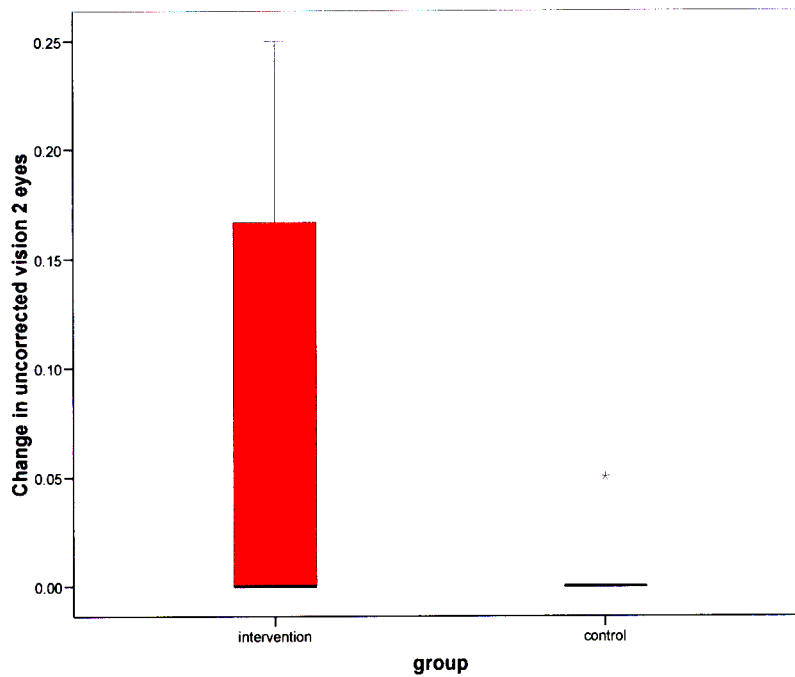
best spectacle corrected vision, binocular uncorrected and best corrected visions) were not significantly different between the two groups (Table 3).

4.2.1 Uncorrected Visual Acuity

Uncorrected vision was naturally presumed to be higher in the treatment group than in the control group since the control group has a large refractive error. The only reason that the treatment group would do the same or worse is if complications of the treatment prevented good vision. The treatment group had vastly superior uncorrected monocular vision and this was highly statistically significant. (Graph 1)



Graph 1: Change in monocular uncorrected visual acuity. The Artisan group improved by a median of 0.45 logMAR compared to 0 logMAR of the control group. (p=0.012)

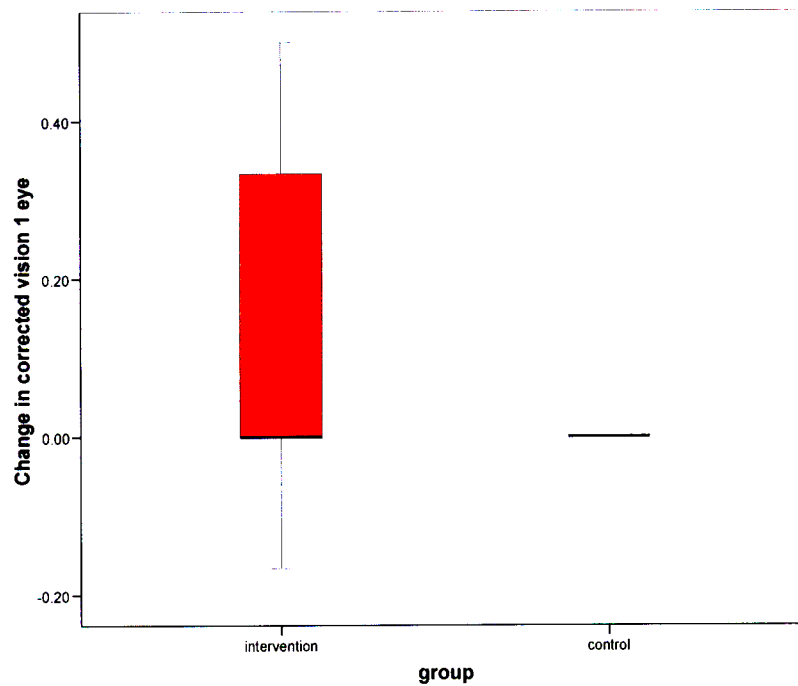


Graph 2: Change in bilateral uncorrected visual acuity: No median change. (p= 0.272)

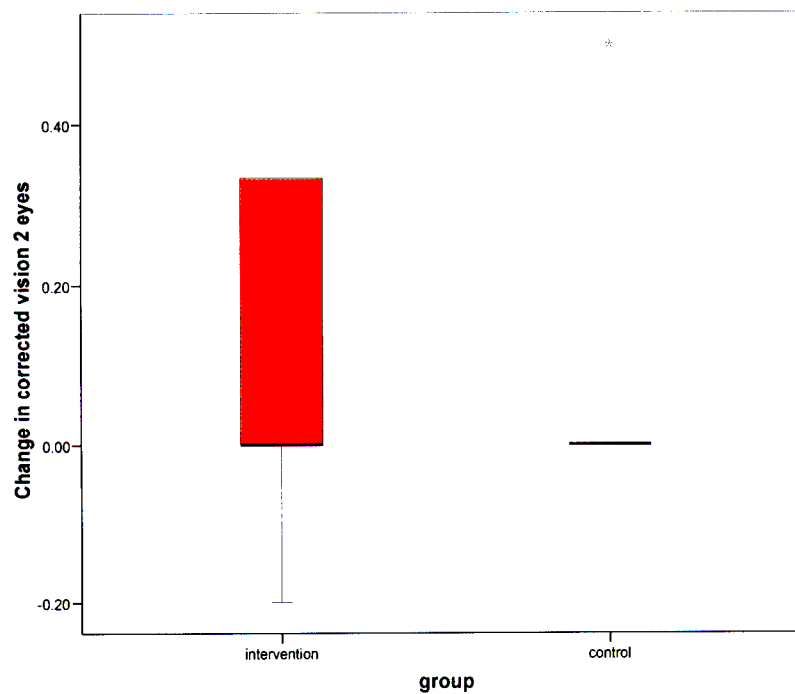
4.2.2 Best Spectacle Corrected Visual Acuity

Best spectacle corrected visual acuity (BSCVA) is the best vision that can be achieved with correct refraction with glasses. Since Artisan implantation should purely be a refractive correction, the BSCVA should remain the same. If the preoperative BSCVA is better than the postoperative the operation is deemed to be unsafe and that some factor has been introduced that is preventing the eye from attaining its full potential.

This study has shown no statistical difference in best-corrected vision (Graphs 3 and 4) and is unlikely to become statistically significant even if more patients were enrolled.



Graph 3: Monocular best spectacle corrected visual acuity. Both groups had a median difference of 0 logMAR. ($p=0.529$)



Graph 4: Binocular best spectacle corrected visual acuity. No statistical difference. ($p=0.955$)

4.2.3 Uveitis

Because previous studies with angle-fixated lenses in Black African patients often caused a severe or chronic inflammation in the eye⁶, this was an important aspect to observe. Clinically, no severe reactions were seen and all inflammation had settled within 1 month of surgery. No patients required prolonged steroid treatment in this iris-fixated lens study.

4.2.4 Stereopsis

No patients in the control group and no patient before implantation in the treatment group, had stereopsis. This is due to the vastly different images seen by the aphakic and phakic eyes. It was not presumed that all patients that received an Artisan implantation would regain 3-dimensional vision because they had lost stereopsis for such a long time. It is reassuring to see that 67% of all treatment patients regained stereopsis without spectacle correction.

4.2.5 Pigment and Glaucoma

The same study as quoted in 4.2.3⁶ also showed that angle-fixated lenses caused pigment dispersion from dark irises. This led to a pigmented angle and pigment deposited on other structures in the anterior chamber of the eye. It was also found that these lenses slowly damaged the angle and that the intraocular pressure rose and caused glaucoma eventually.

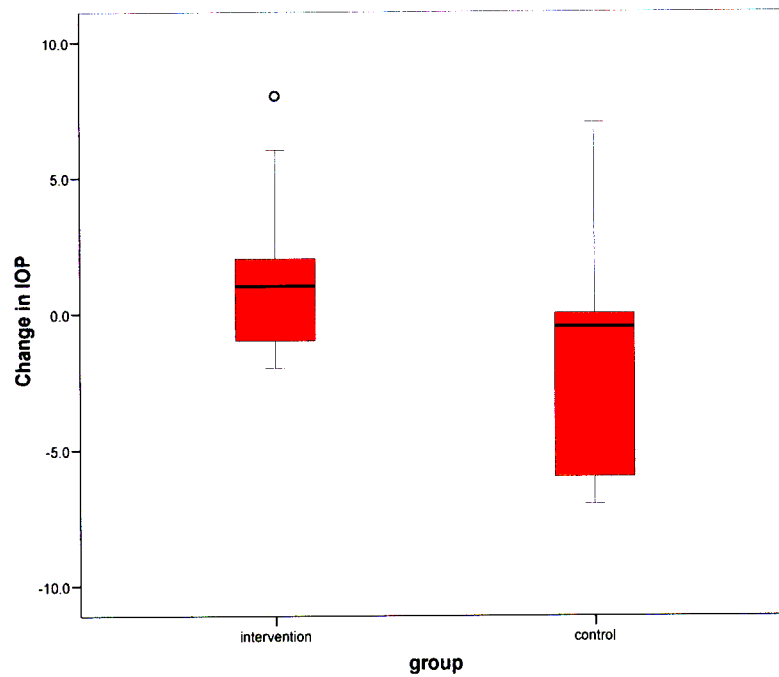
The Artisan lenses in this study did not seem to cause more angle destruction, raised intraocular pressure or glaucoma than in the control group (Graphs 5 and 6).

Patient 5 in the Artisan group had an IOP of 29 at the first visit. Although the pressure was high the patient was not excluded because no glaucomatous cupping was evident and the pressure could be controlled using topical treatment. Patients 2 and 5 in the control group were also not excluded because of the same reason.

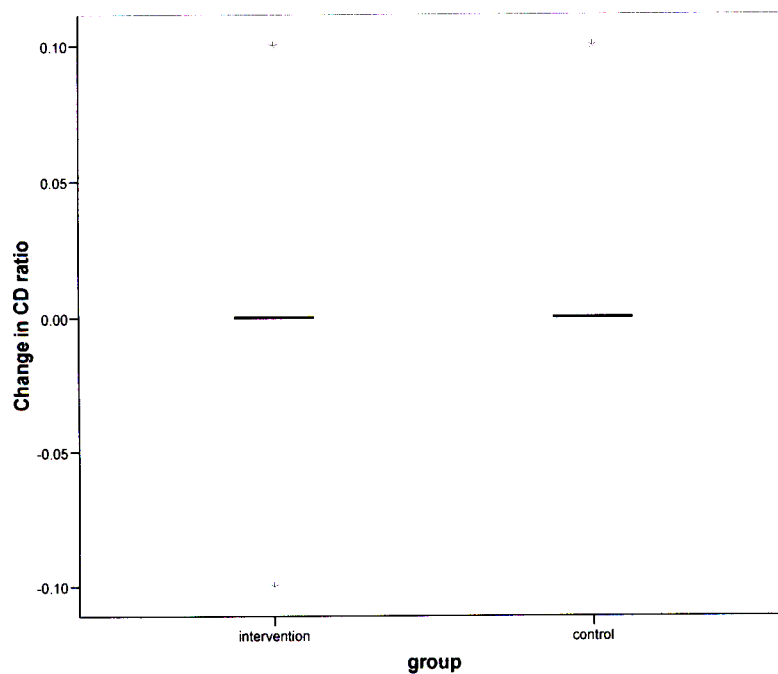
All these patients also had raised IOP at the final visit but only after discontinuation of the drops for a few weeks. This wash out period enabled us to measure the “natural” pressures without any influence from medication. Use of pressure lowering medications could thus be excluded from statistical analyses and eliminated as a confounder.

One patient in each group displayed enlargement of the cup: disc (C:D) ratio from 0,2 to 0,3. Since all C:D measurement were subjective it is conceivable that these changes are in line with measurement inaccuracy. Patient 8 in the Artisan group even seemed to have a reduction in C:D ratio. However all cup enlargement coincided with high baseline IOPs and thus these patients had treatment reinstated and progress monitored.

Thus change in IOP and cupping were similar in both groups and all high pressures could be successfully treated with topical Timoptol® (Timolol 0,25%) or Xalatan® (Latanoprost 0,005%).



Graph 5: Change in intraocular pressure (IOP). The intervention group had a median increase in IOP by 1mmHg and the control group a drop of 0.5mmHg. This is not statistically significant and is unlikely to become significant even if the study had to be completed. ($p=0.388$)



Graph 6: Change in cup-to-disc ratio: No statistical difference. ($p=0.689$)

Pigment changes were also limited. The only iris pigment changes observed were at the enclavation site (Plate 4) and were most probably caused by trauma to that part of the iris during surgery. No other part of the iris developed atrophy.


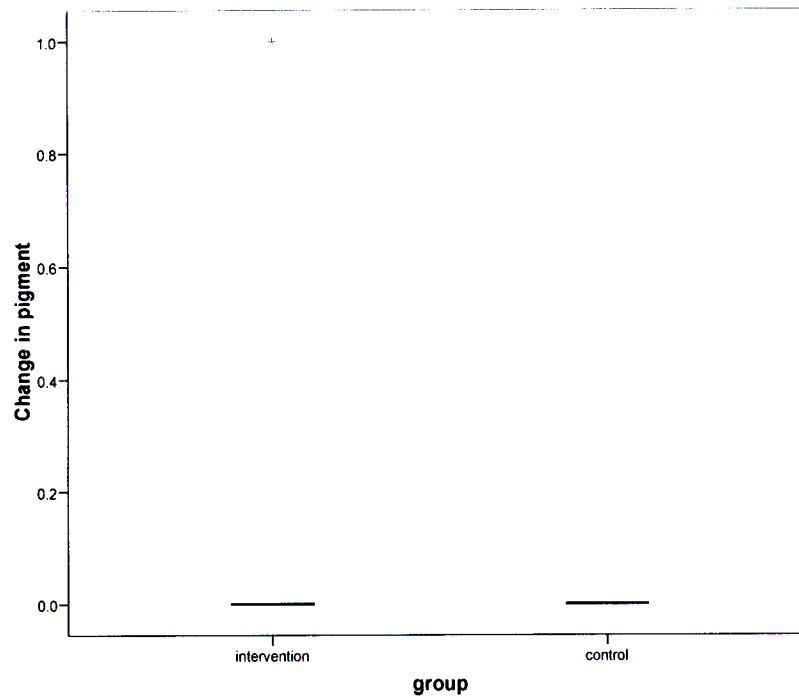


Plate 4: Pigment loss at enclavation site due to surgical technique

There was no statistical change in pigmentation of the angle (Graph 7). This was, however, difficult to assess since most eyes had a very pigmented angle to begin with (Plate 5). The initial trauma causing the aphakia is a possible cause.



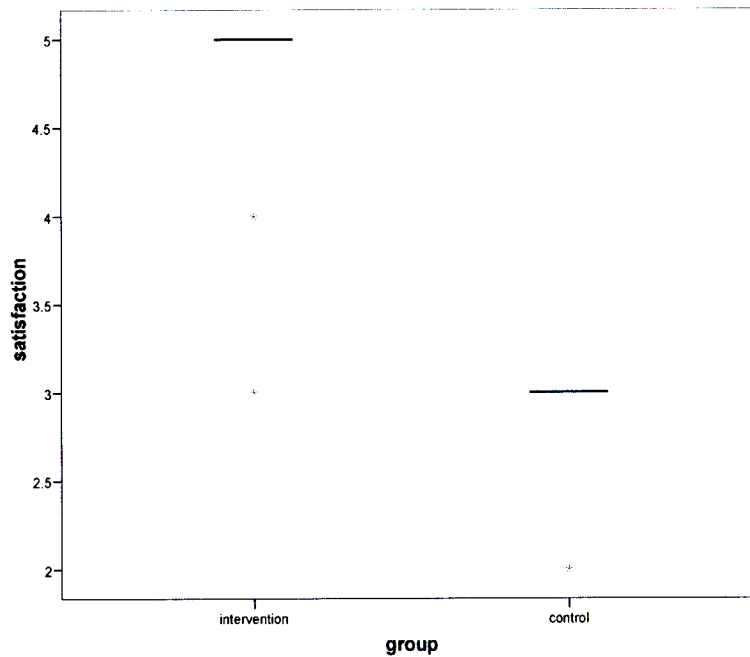
Graph 7: Change in angle pigmentation: No significant change in either group.
($p=0.776$)

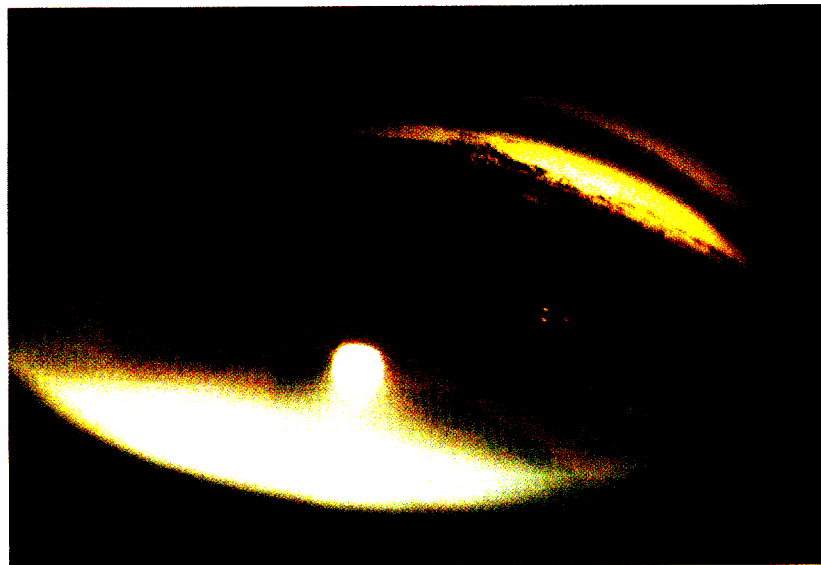

Plate 5: Heavily pigmented angle same before and after operation

4.2.7 Patient Satisfaction

Patient satisfaction was very high in the treatment group and reflected the improvement in quality of life and lack of symptomatic side-effects from the implantation. The control group remained unchanged as was expected. (Graph 8)



Graph 8: Patient satisfaction score: The median of the treated group is 5 “very happy” while the control group median is 3 “same”. ($p=0.002$)

Chapter 5

DISCUSSION

5.1 Clinical Interim Interpretation

Our clinical experience mirrored the statistical results. Subjectively it was felt in the Department of Ophthalmology that the patients receiving the Artisan implant were at a far greater advantage than the control group.

Not only were the treated patients exceedingly satisfied but also the complication rate was acceptably low. A larger group of patients had received the Artisan lens implant outside of the trial than in it, due to the strict entrance and exit criteria. The patients outside the study have also been doing very well. It was becoming increasingly difficult to refuse implantation of the lens on the basis of randomisation into the control group of the study.

5.2 Study Outcomes

5.2.1 Best-Corrected Vision

The equal results in both groups show the procedure to be safe. The measurements did not include correction for the magnifying effect of aphakic spectacles. If this effect were taken into account the treatment group would most likely do even better.

5.2.2 Uncorrected Vision

Although the improvement in monocular vision was large, the average uncorrected vision was only 0.45 logMAR ($\approx 6/14$), which is lower than the expected 1 logMAR (6/6) vision in a normal eye. We felt that the less than perfect vision was due to abnormalities of the eyes caused by the initial insult causing the aphakia.

The worst uncorrected vision in the treatment group after Artisan implantation was only 0.017 logMAR and corrected to 0.13 logMAR with spectacles. This patient was found to have irregular astigmatism from a poorly constructed and sutured limbal wound (Plate 6) made during the initial complicated surgery.

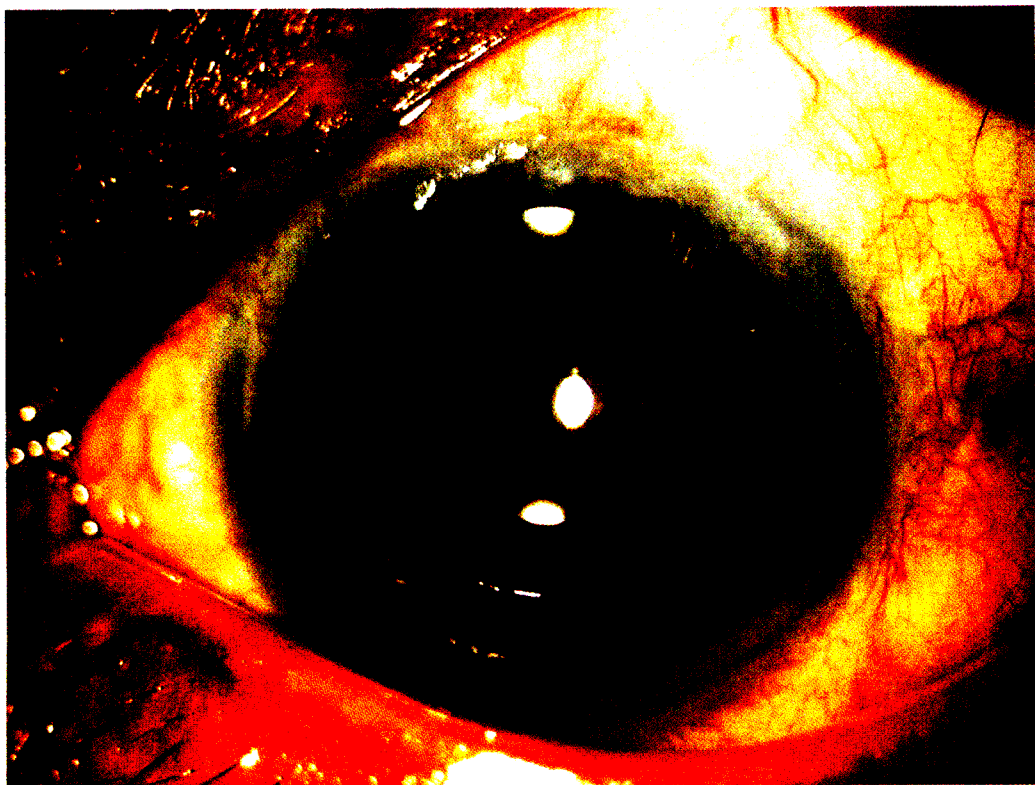


Plate 6: Irregular astigmatism caused by the initial insult, which resulted in the poor final vision. Note the scar at superior limbus and drawn-up pupil.

Although the final visions in the Artisan group were not all 1 logMAR (6/6), these final visions were expected because of the poor initial best spectacle corrected vision. Although no OCT (ocular coherence tomography) was done to confirm the findings, no macular oedema was noted clinically in either group.

5.2.3 Pigment and Glaucoma

All eyes with initially raised pressures remained high or became somewhat higher and all normal pressure eyes remained normal. Raised pressure was therefore felt to be due to pre-existing eye disease such as pseudoexfoliation (Plate 7). During the year's follow up, the average disc size in the treatment group stayed the same. The eye with pseudoexfoliation was randomised to the control group and had an increase in cup size from 0.2 to 0.3.

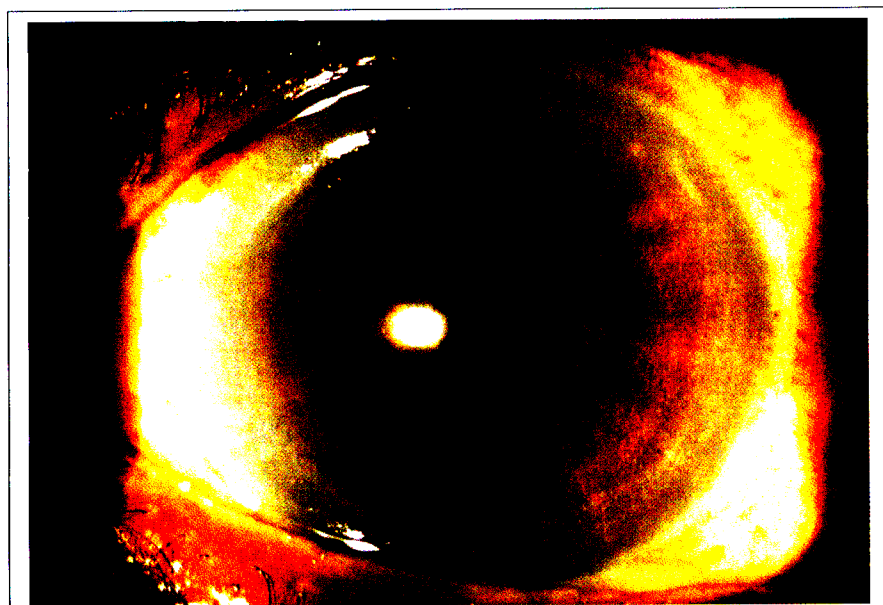


Plate 7: White pseudoexfoliative material on pupillary margin

5.3 Surgery

The surgery was found to be relatively simple with a very small chance of causing damage if the correct prescribed steps were taken. No lenses implanted had to be removed or repositioned.

5.4 Study Shortcomings

The study was not completed according to the initial statistical projection yet statistical significance was achieved with fewer patients. Statistical and ethical considerations prevented the study from continuing.

It seems inequitable to compare a refractively corrected group to an uncorrected group. It has been suggested that a comparison between Artisan implantation and contact lens wear, angle-supported or scleral-fixated lenses would have been more pertinent. This might be the case but the aim of this trial was to compare Artisan lens implantation to the current standard of practice in this setting. The status quo of treating monocular aphakic eyes with inadequate capsular support before this study was to leave the patients uncorrected. A comparison to contact lens wear would have defeated this object of the study.

Although past Artisan studies have shown that most side-effects occur in the first 6 months after surgery this trial included follow up for an entire year. There remains, however, a chance that glaucoma could present many years later. A longer term study of these patients might be pertinent with follow up of 5 to 10 years but further change is unlikely.

Chapter 6

CONCLUSION

Although this randomised, controlled study was terminated early, it has clearly shown the benefit of implanting Artisan®/Verisyse™ lenses into monocular aphakic eyes with no capsular support, even in patients with heavily pigmented irises. This form of refractive correction should become the standard of care for these patients where other options are too expensive or carry higher risk. Leaving such patients uncorrected should no longer be warranted.

REFERENCES

1. The world health report, 1998: life in the 21st century: a vision for all. Geneva: World Health Organization, 1998.
2. Elkington AR, Frank HJ, Greaney MJ. Clinical optics. 3rd ed. Oxford: Blackwell Science, 1999.
3. Menezo JL, Martinez A, Cisneros AL. Iris-fixated Worst claw versus sulcus-fixated PC lenses in the absence of capsular support. *J Cataract Refract Surg.* 1996; 22: 1476-84.
4. Dadeya S, Kamlesh, Kumari Sodhi P. Secondary intraocular lens (IOL) implantation: anterior chamber versus scleral fixation long-term comparative evaluation. *Eur J Ophthalmol.* 2003; 13(7): 627-33.
5. Cook CD, Evans JR, Johnson GJ. Is anterior lens implantation after intracapsular cataract extraction safe in rural black patients in Africa? A pilot study in KwaZulu-Natal, South Africa. *Eye.* 1998; 12 (5): 821-5.
6. Koch DD. Enter with caution. *J Cataract Refract Surg.* 1996; 22(2): 153-4.
7. Worst JGF, van der Veen G, Los LI. Refractive surgery for high myopia. The Worst-Fechner biconcave iris claw lens. *Doc Ophthalmol.* 1990; 75(3-4): 335-41.
8. Worst JGF, Landesz MA. The iris claw lens for correcting high myopia. *Eur J Implant Refract Surg.* 1995 Apr; 7: 119-23.

9. Budo C, Hessloehl JC, Izak M, Luyten GPM, Menezo JL, Sener BA, Tassignon MJ, Termote H, Worst JGF. Multicenter study of the Artisan phakic intraocular lens. *J Cataract Refract Surg.* 2000; 26(8): 1163-71.
10. Fechner PU, Strobel J, Wichmann W. Correction of myopia by implantation of a concave Worst iris claw lens into phakic eyes. *Refract & Corneal Surg.* 1991; 7(4): 286-98.
11. Artisan® Phakic IOL Training Manual. Ophtec BV Groningen. Ophtec BV 2004.
12. Benitez del Castillo JM, Hernandez JL, Iradier JT, Del Rio MT, Garcia Sanchez J. Fluorophotometry in phakic eyes with anterior chamber intraocular lens implantation to correct myopia. *J Cataract Refract Surg.* 1993 Sept; 19(5): 607-9
13. Izak M. Surgical trauma, not lens design is responsible for myopia claw IOL irritation. *Ocul Surg News.* 1998 Sept; 38.
14. Menezo JL. Long term results of surgical treatment of high myopia with Worst-Fechner intraocular lenses. *J Cataract Refract Surg.* 1995; 21(1): 93-8.
15. New device approval: Verisyse™ Phakic IOL - P030028” FDA, Sept 2004. Date accessed: 1 Nov 2007. <http://www.fda.gov/cdrh/pdf3/p030028a.pdf>.
16. Menezo JL, Cisneros AL, Rodriques-Salvador V. Endothelial study of iris-claw phakic lens: four year follow-up. *J Cataract Refract Surg.* 1998; 24(8):1039-49.

17. Landesz MA, Worst JGF, Siertsema JV, van Rij G. Negative implant. A retrospective study. *Doc Ophthalmol.* 1993; 83(4):261-70.
18. Menezo JL, Cisneros AL, Cervera M, Harto M. Iris claw phakic lens intermediate and long-term corneal endothelial changes. *Eur J Implant Refract Surg.* 1994; 6: 195-9.
19. Smith RJH. A new method of estimating the depth of the anterior chamber. *British J Ophthalm.* 1979; 63: 215-220.

ANNEXURE A

Information to Patients

Iris-Claw Lens in African Patients

Dr. Carl-Heinz Kruse
Registrar: Department of Ophthalmology
University of KwaZulu-Natal

Hello, and welcome as a member of this **trial**. Our plan is to see if the new Artisan® lens can help some people to see better. This trial is only for African patients who have no lens in one of their eyes.

We need thirty-six patients for the test: eighteen will get the lens and eighteen will not. This is to test which treatment is better. Neither you, nor the doctor can choose in which group you will be – it will be chosen by **chance**. The results of the trial will be available in about 2 years.

If you are chosen to get the lens you will need to have an **operation**. This operation will feel similar to the cataract surgery you have already had. You will be awake during the procedure, but will get an injection under the eye so that you feel no pain. The procedure will take about 30 minutes. Like the normal cataract surgery we will also make a small cut into the eye to get the lens inside. This lens is **different** because it is only for patients who have no support for the “normal” lens placed behind the iris.

What you need to do:

If you are in the chosen group you have to come to have your surgery done. If all goes well, you will be discharged from hospital the next day.

Everyone must follow up at the clinic at one week, three months, six months and one year after discharge, even if you did not have the operation.

Advantages: You will be given a special card so that you do not have to wait long to see the doctor for these clinic visits. The patients who get the operation may see better, but we don't know yet.

Risks of surgery: There is a less than 1% chance that anything will go permanently wrong (e.g.: infection in the eye, or damage to any part of the eye). The most common problem of this lens is that it could be placed in skew (less than 10% in the European Trial). We will try to prevent any complications and will do our best to correct any problems if they should occur.

All your records will be kept **confidential**. The only people who are allowed to see your information are the doctors, nurses and the bosses of the trial. When the trial is printed, your name will not be mentioned. If you have any questions, or do not want to continue with the trial, please tell your doctor as soon as possible so that the risks can be explained. If you have any complaints or problems please phone 260-4495 or 260-4604.

ANNEXURE B

CONSENT FORM

Title of study: Aphakic Iris-Claw Lens in Low-Income African Population.

I, (Name) _____
hereby consent to an iris-claw intraocular lens implantation in the **left/right** eye on myself.

I acknowledge that I have been informed by:

(Name) _____
concerning the possible advantages and possible adverse effects, which may result from this procedure and of the ways in which it is different from usual cataract surgery.

I, (Name) _____
hereby acknowledge that I understand and accept that this study involves research and the "Information to Patients" leaflet has been handed to me in connection with this study.

I agree that the above procedure will be carried out and/or supervised by

(Name) _____

I acknowledge that I understand the contents of this form, including the information provided in the "Information to Patients" leaflet and as the subject, freely consent to the above procedure being conducted on me.

I am aware that I may withdraw my consent at any time without prejudice to further care.

Signature of Participant

Date

Signature of Witness

Date

Signature of Translator
(Where applicable)

Date

IsiZulu translation also available.

ANNEXURE C



August 2005

To Whom It May Concern:

On the 16th November 2004, Visi Care (Pty) Ltd in conjunction with Ophtec BV, held a wet-lab workshop / CME pertaining to the Artisan Lens.

A formal talk and practice session was overseen by Mr. Jérôme Fissiaux, International Sales and Marketing Manager for Ophtec BV.

This letter serves to confirm that the following doctors from The Department of Ophthalmology in Durban, Kwazulu Natal attended the workshop and participated in the wet lab session:

- Dr.L.Visser
- Dr.K.Naidu
- Dr.F.Adamjee
- Dr.B.Gundry
- Dr.K-H. Kruse

Thank you.

Regards

LAURINDA SUMARES
ACTING CEO
VISICARE (PTY) LTD

JÉRÔME FISSIAUX
INT SALES AND MARKETING MANAGER
OPHTEC BV

VisiCare (Pty) Ltd • PO Box 1010 • Cresta 2118 • Visioned Office Park • Bld V, Upper Level, • 269 Beyers Naude Drive • Northcliff • 2195 • SA
Tel: +27 11-478 3431 • Fax: +27 11-478 0524 • email: info@visicare.co.za • Website: www.visicare.co.za

Directors: Dr. H.L.E. König (Chairman); Dr. F. Moosa; M. Bosman; B. Evans; C. Venter; D. van Wyk
Reg. No.: 9804553/07